

THERAPEUTIC ANGIOGENESIS OF THE LOWER LIMB ISCHEMIA BY AUTOLOGOUS CELLULAR THERAPY

J. Ernesto Novoa Gregorio MD, FUCP
Ministerio de Salud Pública. Montevideo, Uruguay.

Peripheral vascular disease comprises a diverse group of conditions that result in significant morbidity and mortality. Offers an opportunity for the clinician to recognize common but underdiagnosed problems for which effective interventions exist.

Peripheral arterial disease is defined as pathology of the arteries outside the brain and heart. Most manifestations of PAD, follow from the consequences of reduced perfusion of end organs and tissues downstream from sites of flow obstruction. Common forms of PAD include extracranial carotid stenosis, aortoiliac disease and lower extremity occlusive disease (LEOD).

Epidemiologic data suggest that the prevalence of PAD is 12,2% for American adults older than 60 years of age, increasing to 23,2% for those older than 80 years. Risk factors include increased age, diabetes, past or current tobacco use, renal insufficiency, hypertension, dyslipidemia and African American or Hispanic ethnicity.

More than 95% of patients with PAD have one or more risk factors for cardiovascular disease and the diagnosis for either condition should raise suspicion for the other. The 10-year risk of death after a diagnosis of PAD is 40%.

68% of patients with PAD are undiagnosed by their primary care physicians, although as a group these patients have mainly less advanced cases of atherosclerosis.

Risk factors for PAD should merit elicitation of common presenting symptoms, including claudication, limb pain at rest and non healing extremity ulcers for LEOD; and amaurosis fugax, transient ischemic attack, and stroke for carotid occlusive diseases. An appropriate physical examination includes palpation of radial, aortic, femoral, popliteal and pedal pulses; careful examination of distal extremities for stigmata of arterial insufficiency; cervical and abdominal auscultation for carotid and renal bruits; and thorough neurologic evaluation.

Current diagnosis

Carotid artery Diseases

- TIA and stroke
- Bruit and lateralized neurologic deficit
- Carotid ultrasonography, MRA, CTA & carotid angiography

Lower Extremity Occlusive Diseases

- Claudication, rest pain, tissue loss and numbness
- Diminished pulses, hair loss, pallor, cool extremities, tissues wasting, ulcerations and delayed capillary refill (> 3 sec).
- Ankle-brachial index, segmental pressures with waveforms, CTA, MRA and lower extremity angiography.

Lower Extremity Occlusive Disease

LEOD is a common form of peripheral vascular disease in which arterial occlusion or stenosis results in inadequate blood flow to meet peripheral tissue demands. Areas of partial or complete occlusion can occur anywhere from the aorta to the pedal vessels, frequently in the ilio-femoral, femoro-popliteal or tibial arterial systems. The distribution and intensity of symptoms depend on the location and severity of occlusion, the acuteness of onset, and the efficiency of tissue oxygen extraction and utilization. Mild disease can manifest with symptoms of claudication, defined as limb discomfort in specific muscle groups at a reproducible level of exertion.

Severe disease can manifest with pain at rest in the affected extremity , tissue loss or chronic nonhealing wounds.

A distinction should be made between acute and chronic LEOD.

Acute LEOD may result from a thrombotic or embolic event, and is characterized by an abrupt onset of symptoms. Chronic LEOD, is typically less dramatic in presentation and slowly progressive in nature. However many patients present with acute LEOD. Acute LEOD is a surgical emergency and merits urgent evaluation by a vascular surgeon or specialist.

Evaluation

The presenting symptoms of PAD are myriad and include cramping or pain in the legs or hips, cool extremities and diminished extremity sensation. Aproximately 50% of patients have atypical symptoms and the classic symptom of claudication has been observed in only 10% of affected patients in some series. Several classification systems have been established to create uniform standards for evaluation and reporting of PAD. Among them, the Rutherford classification is one of the most commonly used.

Rutherford classification for Peripheral Arterial Occlusive Disease (PAOD)

Symptoms	Grade	Category
Asymptomatic	0	0
Claudication		
Mild	I	1
Moderate	I	2
Severe	I	3
Ischemic rest pain	II	4
Tissue loss		
Minor	III	5
Major	III	6

After careful elicitation of presenting symptoms, a focused physical examination is critical in the diagnosis of LEOD. Physical findings of PAD include reduced or absent pulses, hair loss, pallor, cool extremities, tissue wasting, ulcerations and delayed capillary refill (> 3 seconds).

A useful and inexpensive test for diagnosing and monitoring LEOD is the ankle-brachial index (ABI), which can be readily performed in a clinic. Doppler ultrasonography is used to measure systolic blood pressures in bilateral dorsalis pedis, posterior tibial and brachial arteries. The highest pedal systolic value in each leg is then divided by the highest arm pressure to calculate ABI.

An ABI of greater than 0.9 is considered normal. Claudicants typically have ABIs between 0.5 and 0.9. A value lower than 0.5 is concern for critical limb ischemia and a value lower than 0.3 is often associated with tissue loss. Diabetic patients and paatients with noncompressible tibial vessels secondary to calcification often have falsely elevated ABIs that are not dependable predictors of arterial disease. The numeric value of an ABI might not correlate precisely with symptoms or with vascular imaging findings, but it can be used to monitor progression of disease and should be interpreted in the clinical context.

Treatment

Treatment options for PAD include medical optimization, exercise training, and surgical percutaneous interventions. Patients with mild claudication can benefit from risk factor modification, including smoking cessation and medical optimization for hypertension, diabetes and dislipidemia. The role of antiplatelet therapy in mild claudication is controversial, with mixed results from studies on the FDA-approved agents pentoxifyline and cilostazol. Most claudicants should be prescribed on the basis of cardiovascular risk factors. There is evidence that multimodality therapy is more effective than any single intervention. Supervised exercise regimens have also demonstrated efficacy for some patients with mild and moderate symptoms and should be considered before surgical or percutaneous interventions.

For patients who have not responded to medical optimization, multiple revascularization options exist. The risk and benefits of the proposed procedure must be carefully weighed against potential improvements in quality of life. Indications for revascularization include critical limb ischemia with rest pain, tissue loss, or non healing. Lifestyle-limiting claudication is a relative indication for revascularization.

Surgical revascularization options include bypassing the occluded arterial segment with a venous or synthetic graft and removing plaque from an arterial segment (endarterectomy) with local reconstruction. In the acute setting, removal of thromboembolus can be performed by direct exposure, balloon thrombectomy or purely endovascular techniques. Commonly performed bypass operations that have achieved durable long-term results include aortofemoral bypass for aortoiliac occlusive disease and femoropopliteal and femorotibial bypass for more distal disease. Perioperative morbidity is not insignificant (2%-6%). *In this patient population with substantial comorbidity, complications can include myocardial infarction, wound infection, graft infection, graft thrombosis, limb loss and death.* Long term surveillance of bypass grafts with regular duplex ultrasonographic evaluations is necessary. Endovascular options include angioplasty alone, angioplasty with stenting and atherectomy.

Long segments of occlusion, diffuse lesions and calcified lesions are associated with poor long term outcomes. Routine postintervention surveillance is essential to identify severe restenoses that require secondary intervention.

Therapeutic angiogenesis in arterial limb ischemia by autologous bone marrow transplantation

Peripheral arterial disease (PAD) is a common cause of disability and mortality.

Up to one third of patients are not susceptible to traditional revascularization and may benefit from stem cell therapy.

In meta-analysis of 37 trials, autologous cell therapy was effective in improving surrogate indexes of ischemia, subjective symptoms and hard endpoints (ulcer healing and amputation). On the contrary, G-CSF monotherapy was not associated with significant improvement in the same endpoints. Patients with thromboangiitis obliterans showed some larger benefits than patients with atherosclerotic PAD. The intramuscular route of administration and the use of bone marrow cells seemed somehow more effective than intrarterial administration and the use of mobilized peripheral blood cells. The procedures were well tolerated and generally safe. *This meta-analysis indicates that intramuscular autologous bone marrow cell therapy is a feasible, relatively safe and potentially effective therapeutic strategy for PAD patients, who are not candidate for traditional revascularization.* Larger placebo-controlled, randomized multicenter trials need to be planned and conducted to confirm these findings (Fadini GP, Agostini C and Avogaro A. Autologous stem cell therapy for peripheral arterial disease: Meta-analysis and systematic review of the literature. doi:10.1016/j.atherosclerosis. 2009.08.033)

Our group developed this technique employing the Sondureta Hospital Protocol under the direction of Prof. Joan Besalduch (2003, Spain).

We enrolled critical limb ischemia patients for therapeutic angiogenesis by autologous progenitor cell bone marrow transplantation. They were included from July 2004 to December 2009. We also collected data from 69 patients with critical limb ischemia receiving traditional revascularization as a control treatment (historical population).

Patients with evidence of malignancy in the last five years, IV degree diabetic retinopathy, life expectancy less than 6 months, active infection of the lower limbs, and lymphangitis, were excluded.

Written informed consent was given by each patient. The protocol was approved by the Ethic Committees of the San Carlos Hospital (Uruguay) and the Universidad Autónoma of Nuevo León Hospital (México).

Seventy patients with critical limb ischemia were included from July 2004 to December 2009; 38 men and 32 women. Smokers 60% and diabetics 70% (type 2, 44 and type 1, 5)

We injected filgrastine (G-CSF) 300 ug, subcutaneously during 5 days previous to the bone marrow harvest. Approximately 250 ml of autologous bone marrow were aspirated from the ilium under local anesthesia (lidocaina 2%), and collected in plastic bags containing heparine.

Bone marrow mononuclear cells were sorted by gradient of density on Hidroxiethylstarch 6% (1/6 bone marrow) on a 1500 cpm speed, during 15 minutes. The final volume of BM-MNCs was 40 mL.

The BM-MNCs were implanted by direct intramuscular injection into the gastrocnemius muscle of the ischemic leg (2 ml each site). The median number of implanted mononuclear cells was $2,6 \times 10^9$ /mL and the CD34+ cells $7,9 \times 10^7$ /mL.

For the cell implantation local anesthesia with lidocaine 2% (only 4 patients received general anesthesia with propofol) was used.

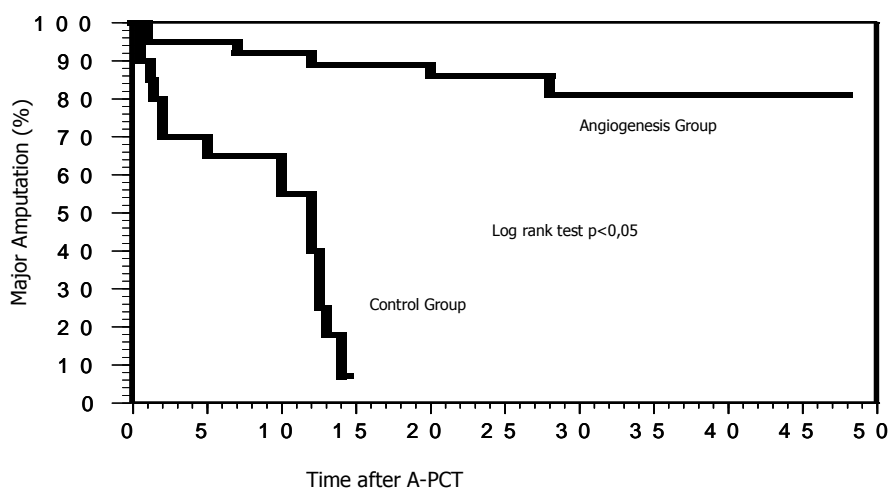
After the procedure, the TA group received enoxaparine 40 mg/scut/day, clopidogrel 75 mg/po/day and pentoxiphiline 400 mg/po/day as antithrombotic schedule for a 60 to 90 days period.

A control population of 69 vascular patients with arterial limb ischemia was considered. They only received the antithrombotic schedule.

The procedure mortality rate was 0%. No side effects were registered related to G-CSF. Moreover, in 70 patients with a 48 months median follow up, 63 of them showed an improvement in the evaluated parameters, rest pain, peack walking time and ulcers healing. Major amputation was necessary in 5 patiens of the TA group (7,1 %). On control population, major amputation was developed in 100% of patients in the first 18 months of outcome.

The differences between the two groups were statistically significant in order to compare rest pain, walking distance, ulcer healing and major amputation rates.

Autologous Progenitor Cell Transplantation for Therapeutic Angiogenesis in Patients with Critical Limb Ischemia (CLI)



Novoa JE, Medina A, Gordillo F et al.
XXII Congress of the CLAHT Group.
September 1-3, 2011. Montevideo, Uruguay

Our data suggested that autologous bone marrow derived progenitor cell transplantation can be performed safely and represent an efficient therapy for no-option patients with peripheral arterial limb disease.

References

- 1 Novoa JE, Medina MA, Perez Chavez F et al. Terapia Celular para el Siglo XXI. Nuestra experiencia en Medicina Regenerativa. Ed Oficina del libro FEFMUR. Montevideo, Abril 2008.
 - 2 Novoa JE. Angiogénesis terapéutica en la isquemia crítica de miembros inferiores mediante terapia celular autóloga. Congreso Internacional de Trombosis & Hemostasis de la Liga del Danubio contra la Trombosis y las Enfermedades Hemorrágicas. Timisoara, mayo 2011.
 - 3 Hernandez P, Artaza H, Diaz AJ et al. Autotrasplante de células madre adultas en miembros inferiores con isquemia crítica. Spanish Journal Surgical Research 2007;vol 4(11):204-211.
 - 4 Besalduch J, Lara R, Sampol A et al. Therapeutic angiogenesis in critical ischemia by implantation of autologous hematopoietic cells. Blood 106,abstr 4222, November 2005.
 - 5 Stakute L, Oyama Y, Pearce W, Yaung K, Villa M, Burt RK et al.AC133+ Stem Cell Therapy for Patients with Severe Peripheral Vascular Disease. Bone Marrow Transplant Meetings. Honolulu, Hawaii, USA. Febrero 14-20, 2006.
 - 6 Catalano M. Epidemiology of critical leg ischemia; North Italian Data. Eur J Med 1993; 2:11-14.
 - 7 Wolfe JHN. Defining the outcome of critical ischaemia a 1 year prospective study. Br J Surg 1986;73:321.
 - 8 Tateishi-Yuyama E, Matsubara H, Morohara T et al. Therapeutic angiogenesis for patients with limb ischemia by autologous transplantation of bone marrow cells: a pilot study and a randomized controlled trial. Lancet 2002;360:427-435.
 - 9 Lederman R, Mendelsohn F, Anderson R et al. Therapeutic angiogenesis with recombinant fibroblast growth factor-2 for intermittent claudication (TRAFFIC study): a randomized trial. Lancet 2002;359:2058-68.
 - 10 Jonson B, Scou T. Outcome of symptomatic leg ischemia: for year morbidity and mortality in Vadstena, Sweden. Eur J Vasc Endovasc Surg. 1996;11:153-7.
 - 11 Taupin P. Stem Cells & Regenerative Medicine. Vol II. Embryonic and adult stem cells. Ed Nova Publishers Inc. New York 2008.
 - 12 Parekkadan B, Yarmush ML. Methods in bioengineering. Stem Cell Bioengineering. Ed. Artech House. Boston London 2010.
 - 13 Audet J & Stanford WL. Stem Cells in Regenerative Medicine. Methods and Protocols. Methods in Molecular Biology 482. Human Press. Toronto, Canada 2010.
 - 14 Burnside WB & Ellsley RH. Stem Cell Applications in Disease and Health. Ed Nova Publishers Inc. New York 2010.
-